

Case report - Congenital

Surgical removal of an embolised patent ductus arteriosus amplatzer occluding device in a 4-year-old girl

Syed Shahabuddin, Mehnaz Atiq, Mohammad Hamid, Muneer Amanullah*

Division of Congenital Cardiac Surgery, Department of Surgery, Cardiothoracic Surgery Section, The Aga Khan University Hospital, PO Box 3500, Stadium Road, Karachi 74800, Pakistan

Received 16 January 2007; received in revised form 3 May 2007; accepted 7 May 2007

Abstract

Alternative strategy of non-surgical closure of patent ductus arteriosus (PDA) is presently the first line of therapy. Several devices are being used for transcatheter closure of PDA. A four-year-old girl underwent a second attempt at PDA closure with an amplatzer device. However, after the deployment of the device it got dislodged into the right pulmonary artery hilum. Several attempts by catheter retrieval failed. The girl underwent surgical removal of the device which was complicated by pulmonary artery injury and subsequent repair was performed on cardiopulmonary bypass.

© 2007 Published by European Association for Cardio-Thoracic Surgery. All rights reserved.

Keywords: Device embolization; Patent ductus arteriosus; Cardiopulmonary bypass

1. Introduction

Alternative strategy of non-surgical closure of patent ductus arteriosus (PDA) is well established [1–4]. This approach involves placement of intra-ductal plug or occlusion device with reasonable success as far as long-term outcome is concerned [4]. However, the disadvantages include longer procedure related time, introduction of intravascular foreign body with potential for misplacement and embolisation. Several devices are being used for transcatheter closure of PDA [5]. We present an emergency situation with an embolised device in the right pulmonary artery.

2. Case report

A four-year-old girl presented with failure to thrive, shortness of breath and easy fatigability. She had pallor, a bounding pulse, and a continuous murmur. An assessment of hypertensive PDA was confirmed on echocardiography. She underwent right heart catheterisation which identified a 10-mm PDA. The homodynamic data showed a pulmonary artery pressure of 102/57 mmHg, with an aortic pressure of 106/59 mmHg. The QP/QS=1.9:1. Pulmonary vascular resistance (PVR) was 6.3 Woods units. Balloon occlusion showed a drop in pulmonary pressures to half systemic. An amplatzer muscular ventricular septal defect device was used but slipped out of the PDA due to small size of the device. The procedure was abandoned.

She was readmitted three months later and under IV sedation, transcatheter closure with a bigger size device was performed. A 12-mm amplatzer muscular ventricular septal defect occlusion device was deployed with satisfactory results. The next morning there was a palpable thrill with echocardiographic evidence of PDA. A chest X-ray confirmed the device to be lodged at hilum of the right pulmonary artery (RPA) (Fig. 1a). She was brought back to the angiographic suite and several attempts to retrieve the device failed (Fig. 1b).

The girl was shifted to the operating room. Median sternotomy was performed and dissection was carried out around the aorta, pulmonary artery and PDA. The device was felt in the RPA (Fig. 2). The RPA was cross-clamped and an arteriotomy over the device facilitated its removal. The process of device removal was complicated by massive bleeding from a tear in the pulmonary artery. The patient became bradycardiac and hypotensive. Emergency cardiopulmonary bypass (CPB) was established via aortic and right atrial venous cannulae. The PDA was ligated and transfixed. The pulmonary artery was repaired primarily. The patient was weaned off CPB uneventfully and extubated the next morning, and discharged home on the third postoperative day. Postoperative echo demonstrated a minute flow across the PDA with no haemodynamic effect.

3. Discussion

Technological advances have made non-surgical closure of patent ductus arteriosus simple and a routine angiographic procedure. The use of amplatzer muscular ventricular septal defect device has further refined and improved the

*Corresponding author. Tel.: +92 21 493 0051 Ext: 4708; fax: +92 21 493 2095.

E-mail address: muneer.amanullah@aku.edu (M. Amanullah).

© 2007 Published by European Association for Cardio-Thoracic Surgery

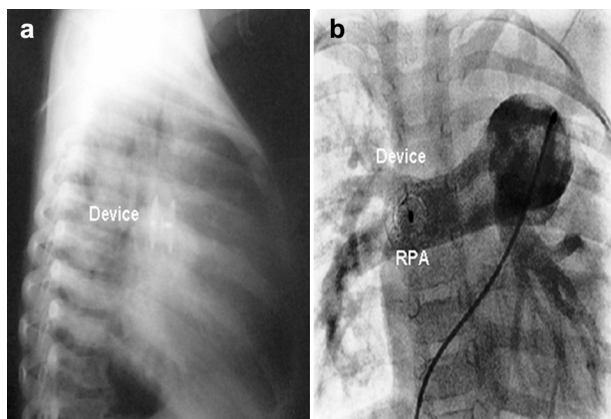


Fig. 1. (a) Lateral chest X-ray showing the amplatzer device in the pulmonary artery position. (b) AP view at cardiac angiography showing the amplatzer device at the right pulmonary hilum.

results of percutaneous PDA closure with minimal complications [6]. However, there are situations where complications are encountered and surgical help is required to ameliorate the issue [7]. Faella and colleagues reported 15 procedure-related complications in 316 patients including haemolysis, left pulmonary artery stenosis, device protrusion into the aorta causing coarctation, device misplacement, and one death following device embolisation [8]. Late embolisation of a device to the left pulmonary artery has been reported with impaired left pulmonary perfusion six months after percutaneous procedure, requiring open heart surgery for retrieval [9]. Similarly, a misplaced coil requires surgical removal on cardiopulmonary bypass [10]. Whether the size of the device has any bearing to the rate of failure is controversial; people have successfully deployed an oversized device [6].

In our case we took the child to the operating room immediately after attempts at removal via transcatheter

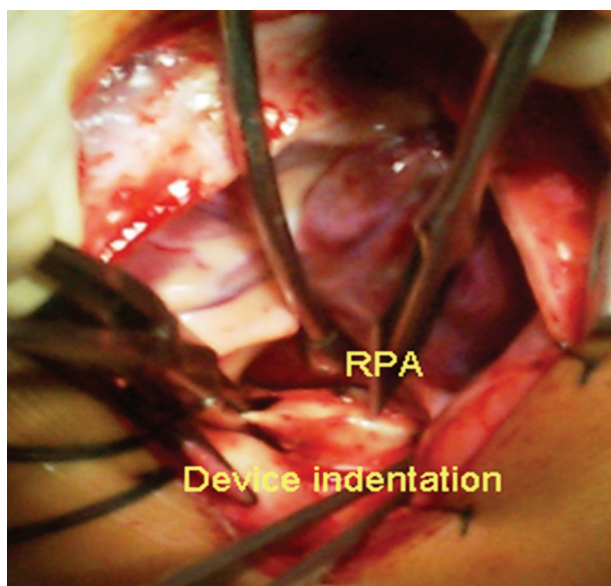


Fig. 2. Operative view of the right pulmonary artery with the indentation made with the embolised amplatzer device.

retrieval failed. The device was retrieved from the right pulmonary artery without going on cardiopulmonary bypass. However, in so doing the delicate and somewhat bruised pulmonary artery gave away. The significant blood loss led to haemodynamic compromise and ended up requiring emergency cardiopulmonary bypass and repair of RPA.

We decided to approach the PDA via median sternotomy for two reasons. This approach gave us a good control of the major vessels and enhanced our ability to go on CPB if major adverse events are encountered. That is exactly what happened. Secondly, the device embolised to the RPA which would have necessitated a right thoracotomy; on the contrary the PDA closure is carried out via a left thoracotomy.

Transcatheter closure of PDA is effective and safe but there are subsets of patients with large PDA and pulmonary hypertension that can lead to complications. This case report highlights the importance of backup surgical cover which is complimentary to non-surgical closure of patent ductus arteriosus and its importance cannot be ignored as surgical support with the facility of cardiopulmonary bypass saved the child's life.

References

- [1] Verin VE, Savetiev VS, Kolody SM, Prokubovski VI. Results of transcatheter closure of the patent ductus arteriosus with the Botallooccluder. *J Am Coll Cardiol* 1993;22:1509–1514.
- [2] Hijazi ZM, Geggel RL. Results of antegrade multiple transcatheter of patent ductus arteriosus using single or Gianturco coils. *J Am Coll Cardiol* 1994;74:925–929.
- [3] Rao PS, Kim SH, Choi JY, Rey C, Haddad J, Marcon F, Walsh K, Sideris EB. Follow-up results of transvenous occlusion of patent ducts arteries with the buttoned device. *J Am Coll Cardio* 1999;33:820–826.
- [4] Masura J, Tittel P, Gavora P, Podnar T. Long-term outcome of transcatheter patent ductus arteriosus closure using amplatzer duct occluders. *Am Heart J* 2006;151:755e7–10.
- [5] Arora R, Sengupta P, Thakur AK, Mehta V, Trehan V. Pediatric Interventional Cardiac Symposium (PICS-VI) device closure of patent ductus arteriosus. *Interven Cardiol* 2003;16:385–391.
- [6] Thanopoulos B, Hakim FA, Hiari A, Goussous Y, Basta E, Zarayelyan AA, Tsaousis GS. Further experience with transcatheter closure of the patent ductus arteriosus using the amplatzer duct occluder. *J Am Coll Cardiol* 2000;35:1016–1021.
- [7] Duke C, Chan KC. Aortic obstruction caused by device occlusion of patent arterial duct. *Heart* 1999;82:109–111.
- [8] Faella HJ, Hijazi ZM. Closure of the patent ductus arteriosus with the amplatzer PDA device: immediate results of the international clinical trial. *Cardiovasc Intervent* 2000;51:50–54.
- [9] Atik FA, Jatene FB, Paulo Henrique N, Costa PH, Atik E, Barbero-Marcial M, Almeida de Oliveira S. Surgical treatment of coil embolisation to the pulmonary artery after an attempt at percutaneous closure of patent ductus arteriosus. *Arq Bras Cardiol* vol.83 no.1 SãoPaulo July 2004.
- [10] Chowdhury SK, Ranjit MS, Saldanha R, Balakrishnan KR. Surgical retrieval of malpositioned ductal coil. *Asian Cardiovasc Thorac Ann* 2001; 9:330–331.

ICVTS on-line discussion A

Title: Endovascular closure of PDA with the use of occluders

Authors: Leo A. Bockeria, Bakoulev Scientific Center, Roublevskoye Shosse 135, Moscow 121552, Russia; Bagrat G. Alekryan, Manolis G. Pursanov, Ashot M. Grigoryan
doi:10.1510/icvts.2007.152298A

eComment: Endovascular closure of PDA with the use of amplatzer duct occluder proved effective in the clinical practice [1]. The use of this occluder